

NORTH SHORE MAGNETIC IMAGING CENTER

A joint venture of Addison Gilbert, Beverly and Salem Hospitals and AtlantiCare Medical Center

FALL 1999

ACUTE STROKE ASSESSEMENT by MR EVALUATION

By: Howard Lowy, MD

Clinical Director, North Shore Magnetic Imaging Center, Inc.

Approximately 85% of strokes result from ischemia relating to embolic or thrombotic vascular occlusion. When brain blood supply falls to approximately 20% of normal, the cellular sodium-potassium pump fails, and water and sodium enter cells resulting in cytotoxic edema. This initially reversible ischemic cellular injury can progress to irreversible cell death. With cellular death there will be blood brain barrier break-down and vasogenic edema. With ischemic infarction, CT will be normal in the first few hours. After a few hours conventional MRI will be abnormal while CT studies will generally still be normal. More recently, with a newer MRI technique called echo planar imaging (EPI) diffusion weighted imaging, the diagnosis of acute ischemic infarction can be made within minutes rather than hours. (See figures 1 & 2). Diffusion images are sensitive to restricted water diffusion as occurs with cytotoxic edema due to acute ischemia. Chronic infarcts will not show abnormal signal on diffusion images. Therefore, one use of diffusion imaging is to demonstrate acute infarct that co-exists (perhaps contiguous or continuous) with old infarcts.

(See figures 3 & 4).

continued on page 2

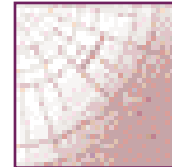
YEAR 2000

North Shore Magnetic Imaging Center has recognized the importance of being ready for the "Year 2000". A committee has been formed to address any issues that may arise at the Center after 12/31/1999. A Year 2000 Readiness Plan has been designed. Steps are actively being taken to try to minimize any potential adverse effects on patient care services. If you have any questions or comments about North Shore Magnetic Imaging Center's Year 2000 Readiness Plan, please do not hesitate to contact Mary Ellen Tobey at (978) 532-8960.

WHAT'S INSIDE

Expanded MRA . . .pgs 4-5
Coverage

ICD-9 Codespgs 6-7



68 Prospect Street, Peabody, MA 01960

A joint venture of Addison Gilbert, Beverly and Salem Hospitals and AtlantiCare Medical Center

NORTH SHORE MAGNETIC IMAGING CENTER

NON PROFIT ORG.
U.S. POSTAGE
PAID
PEABODY, MA
PERMIT NO. 40